



Allergologia et immunopathologia

Sociedad Española de Inmunología Clínica,
Alergología y Asma Pediátrica

www.all-imm.com



CASE REPORT

OPEN ACCESS

Methotrexate might become the sole treatment option for leukemia following the occurrence of Stevens-Johnson syndrome

Carolina Sanchez Aranda^{a*}, Katherine Maciel Costa Silvestre^a, Kamila da Silva Marques^b, Maria Lucia Lee^c, Dirceu Solé^a

^aUniversidade Federal de São Paulo, São Paulo, Brazil

^bSão José dos Campos Educacional, São Paulo, Brazil

^cBeneficência Portuguesa de São Paulo, São Paulo, Brazil

Received 26 August 2023; Accepted 23 November 2023

Available online 1 July 2024

KEYWORDS

allergy;
drug allergy;
children;
Stevens-Johnson
syndrome;
leukemia

Abstract

Introduction: Severe cutaneous adverse reactions (SCARs) arising from drug interactions can carry life-threatening implications and result in lasting effects. SCARs can be triggered by various factors, with trimethoprim/sulfamethoxazole identified as a primary culprit. Anticonvulsants and antineoplastic agents have been noted as secondary triggers. Notably, antineoplastics linked to SCARs include immunomodulatory agents. The higher mortality rates among cancer patients with SCARs underscore the significance of comprehending cancer-specific risk factors. Our objective is to present the case of a boy with acute lymphocytic leukemia (ALL) who developed Stevens-Johnson syndrome (SJS) following MTX treatment.

Case report: We present the case of a three-year-old male patient diagnosed with ALL who developed Stevens-Johnson syndrome (SJS) subsequent to the administration of MTX, following the “BFM 2009” protocol. He had undergone intrathecal MTX administration on six previous occasions. Our patient received IVIG at a dose of 2g/kg along with steroids, resulting in partial clinical improvement after 21 days. An innovative protocol was developed, involving IVIG before MTX infusion and dexamethasone before MTXi, with folinic acid rescue. Intravenous immunoglobulin (IVIG) mitigates SJS/TEN via type IV hypersensitivity down-regulation and apoptosis curbing.

Conclusion: As far as we know, the prophylactic use of IVIG to counteract SCARs in a pediatric leukemia patient represents uncharted territory. Moreover, research into the immune system dynamics within these patients and the preservation of indispensable treatments should involve allergist-immunologists as part of the multidisciplinary team attending to neoplastic conditions.

© 2024 Codon Publications. Published by Codon Publications.

*Corresponding author: Carolina Sanchez Aranda, Universidade Federal de São Paulo, São Paulo, Brazil. Email address: carolaaranda@yahoo.com.br

<https://doi.org/10.15586/aei.v52i4.983>

Copyright: Aranda CS, et al.

License: This open access article is licensed under Creative Commons Attribution 4.0 International (CC BY 4.0). <http://creativecommons.org/>

Introduction

Severe cutaneous adverse reactions (SCARs) to drugs can be life-threatening and responsible for drastic, potentially chronic sequelae. SCARs to drugs cover a broad spectrum of entities mainly consisting of Stevens-Johnson syndrome, toxic epidermal necrolysis (SJS/TEN), and drug reaction with eosinophilia and systemic symptoms (DRESS) syndrome.¹

Incidence rates of SJS/TEN reported in the general population range from 2 to 7 cases per million per year.¹ A recent large observational study on the epidemiology of SJS/TEN published in the *Journal of Investigative Dermatology* showed that active cancer may be associated with an increased risk of SJS/TEN.² This finding is consistent with the EuroSCAR study that reported an increased risk (relative risk+ 2.7) of SJS/TEN in individuals with active malignancy.² Confirmed cases of SJS/TEN were more common in hematologic diagnoses compared with solid malignancies (0.1% vs. 0.007%, $P < 0.0001$).³

The most common identified triggers of SJS/TEN were antibiotics (53.2%), with trimethoprim/sulfamethoxazole being the most frequent (22.6%). Anticonvulsants (e.g., phenytoin) and antineoplastic agents were the second triggers (9.7% each). SJS-/TEN-related antineoplastics included immunomodulatory agents (lenalidomide, interferon, and methotrexate - MTX).² Cancer patients have increased mortality rates from SJS/TEN compared with individuals without cancer; therefore, a thorough understanding of the factors that increase risk in cancer patients is especially critical.²

The immunosuppression of many cancer patients and the higher prevalence of SJS/TEN in patients with HIV suggest the possibility of the immune system's role in increasing the risk of SJS/TEN.⁴ Another explanation relates to increased exposure to multiple drugs in cancer patients.⁵

Case Report

We reported a 3-year-old male patient diagnosed with acute lymphocytic leukemia (ALL) that evolved with SJS after receiving MTX according to the "BFM 2009" protocol. He had been submitted to an intrathecal application with MTX on six previous occasions.

In this context, the patient initially presented with pain and warmth in the first toe of the left foot, with no history of trauma, which subsequently progressed to arthritis in the left knee. Upon admission, infectious arthritis was considered as a hypothesis until a blood count revealed blasts during diagnostic tests. A diagnosis of acute B lymphoid leukemia was established.

After 6 months, chemotherapy was resumed, with the patient receiving mercaptopurine (50 mg/m²/day) and methotrexate (2 g/m² in 24 hours intravenously). Subsequently, the patient developed skin lesions accompanied by persistent fever. These lesions were flat and erythematous, originating on the trunk, and had spread to the limbs and face. They also affected the oral mucosa and lips, leading to facial and extremity edema, conjunctivitis, and the formation of bullous lesions within 12 hours. Numerous target lesions were observed, primarily on the

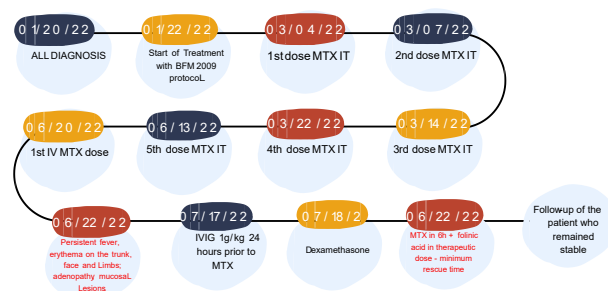


Figure 1 Timeline of patient-reported events.

fingers. No significant changes were noted in the blood count that would suggest intoxication or methotrexate-induced epidermal necrosis.

Given the suspicion of SJS, a skin biopsy was performed, and the patient received 1 g/kg/day of immunoglobulin for 3 days. Dermis with infiltration of inflammatory cells, predominance lymphocytes, and epidermal necrosis. In addition, changes in the dermis-epidermis junction indicated the presence of subepidermal blisters, characterized by vacuolar changes. Keratinocyte dystrophy was not present (Figure 1 presented a timeline).

During the acute phase, the patient required intensive care support due to SCARs that led to multiorgan failure and fluid loss due to skin damage. Antibiotic prophylaxis is not recommended, and the prescription of unnecessary or nonessential medications should be avoided.⁶ The efficacy of several immunosuppressants or immunomodulatory treatments remains controversial.⁶ In many centers, systemic corticosteroids are the preferred treatment option. While the use of human immunoglobulin (IVIG) as a treatment for SJS/TEN has yielded inconsistent results, numerous publications emphasize its benefits. Cyclosporin, an anti-apoptotic agent, has also been suggested to inhibit CD8+ T-cells, thereby limiting disease progression following its administration.⁶ Our patient received IVIG at a dose of 2 g/kg along with steroids, resulting in partial clinical improvement after 21 days.

The only therapeutic option for this leukemia required three additional cycles of MTX. Consequently, after extensive deliberation with the oncology team and the family, an innovative protocol was devised, and the family provided formal consent (informed consent) for its implementation. Our approach involved administering IVIG (1 g/kg) 24 hours prior to MTX infusion (MTXi) and administering dexamethasone (equivalent to a dose of 2 mg/kg/day of prednisone) immediately before MTXi, along with rescue therapy using folic acid in the shortest possible duration to minimize drug circulation in the bloodstream (Figure 2).

Discussion

Intravenous immunoglobulin (IVIG) stands out as a treatment option for SJS/TEN due to its ability to downregulate type IV hypersensitivity and curb cell apoptosis. The rationale behind utilizing high doses of IVIG is to modify lymphocyte migration and impede the mechanism involving the cell surface Fas receptor (Fas) and Fas ligand (FasL).

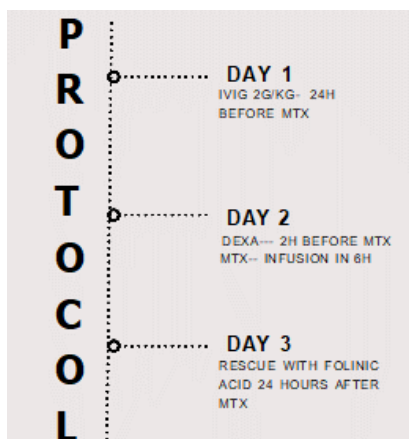


Figure 2 Protocol used for the patient to receive MTX.

Activation of Fas by FasL leads to apoptotic cell death, mediated through caspase activation. Alongside the Fas-FasL interaction explaining epidermal cell death through substantial T-cell-mediated necrosis and apoptosis, additional pathways like the perforin-granzyme B pathway and the agranulysin-induced pathway merit discussion.^{7,8}

Granulysin, a proapoptotic protein predominantly released by CTLs and NK cells, assumes a pivotal role as a mediator of keratinocyte apoptosis, crucial in the widespread epidermal necrosis characteristic of SJS/TEM. Notably, evidence suggests that IVIG treatment could reduce the number of NK cells in peripheral blood and curtail the release of granzyme B into plasma.⁹ Studies indicate that IVIG leads to reduced internalization into antigen-presenting cells, resulting in a diminished antigen-specific CD4⁺ T-cell response and suppression of CD8⁺ T-cells and cytotoxic markers such as perforin.⁹

The patient successfully completed the three missing cycles without encountering adverse clinical manifestations and achieved remission of ALL thus far. Certain conditions present only a single therapeutic option of greater efficacy. Consequently, while several desensitization protocols for IgE-mediated reactions have been employed,¹⁰ such an approach is infeasible for cell-mediated reactions.

The administration of IVIG in conjunction with corticosteroids and calcineurin inhibitors holds the potential to mitigate inflammation and disrupt immunological mechanisms. This could offer a therapeutic avenue in scenarios necessitating the use of culprit drugs for SCARs. The patient concluded the treatment involving intravenous MTX and now maintains with weekly oral MTX alongside IVIG at a dosage of 1 g/kg every other week. This case outlines the narrative of a patient who experienced SCARs due to MTX usage. The initiating drug was indispensable for the patient's treatment and recovery. As per existing literature,¹¹ immunomodulation using high doses of immunoglobulin is suggested as a potential treatment option in such cases.

Conclusion

To the best of our knowledge, the prophylactic use of IVIG to mitigate SCARs in a pediatric patient with leukemia

remains a topic with limited understanding and represents a highly challenging intervention. The search for biomarkers and further investigations remains imperative for the effective management of SCARs in individuals with cancer. In addition, research into the dynamics of these patients' immune system and the preservation of indispensable treatments should include allergist-immunologists as part of the multidisciplinary team that attends to neoplastic conditions.

Conflict of interest

None

References

1. Chung W-H, Wang C-W, Dao R-L. Severe cutaneous adverse drug reactions. *J Dermatol.* 2016;43(7):758-66. <https://doi.org/10.1111/1346-8138.13430>
2. Gillis NK, Hicks JK, Bell GC, Daly AJ, Kanetsky PA, McLeod HL. Incidence and triggers of Stevens-Johnson syndrome and toxic epidermal necrolysis in a large cancer patient cohort. *J Invest Dermatol.* 2017;137(9):2021-2023. <https://doi.org/10.1016/j.jid.2017.05.010>
3. Macedo FI, Faris J, Lum LG, Gabali A, Uberti JP, Ratanatharathorn V, et al. Extensive toxic epidermal necrolysis versus acute graft versus host disease after allogeneic hematopoietic stem-cell transplantation: challenges in diagnosis and management. *J Burn Care Res.* 2014;35(6):e431-5.
4. Wu J, Lee YY, Su SC, Wu TS, Kao KC, Huang CC, et al. Stevens-Johnson syndrome and toxic epidermal necrolysis in patients with malignancies. *Br J Dermatol.* 2015;173(5):1224-31.
5. Frey N, Jossi J, Bodmer M, Bircher A, Jick SS, Meier CR, et al. The Epidemiology of Stevens-Johnson Syndrome and Toxic Epidermal Necrolysis in the UK. *J Invest Dermatol.* 2017;137(6):1240-1247. <https://doi.org/10.1016/j.jid.2017.01.031>
6. Jacobsen A, Olabi B, Langley A, Beecker J, Mutter E, Shelley A, et al. Systemic interventions for treatment of Stevens-Johnson syndrome (SJS), toxic epidermal necrolysis (TEN), and SJS/TEN overlap syndrome. *Cochrane Database Syst Rev.* 2022;3(3):CD013130. <https://doi.org/10.1002/14651858.CD013130.pub2>
7. Saeed HN, Chodosh J. Immunologic Mediators in Stevens-Johnson Syndrome and Toxic Epidermal Necrolysis. *Semin Ophthalmol.* 2016;31(1-2):85-90. <https://doi.org/10.3109/08820538.2015.1115255>
8. Ye LP, Zhang C, Zhu QX. The Effect of Intravenous Immunoglobulin Combined with Corticosteroid on the Progression of Stevens-Johnson Syndrome and Toxic Epidermal Necrolysis: A Meta-Analysis. *PLoS ONE.* 2016;11(11):e0167120. <https://doi.org/10.1371/journal.pone.0167120>
9. Saeed HN, Chodosh J. Immunologic Mediators in Stevens-Johnson Syndrome and Toxic Epidermal Necrolysis. *Semin Ophthalmol.* 2016;31(1-2):85-90. <https://doi.org/10.3109/08820538.2015.1115255>
10. Castells MC, Tennant NM, Sloane DE, Hsu FI, Barrett NA, Hong DI, et al. Hypersensitivity reactions to chemotherapy: outcomes and safety of rapid desensitization in 413 cases. *J Allergy Clin Immunol.* 2008;122(3):574-80. <https://doi.org/10.1016/j.jaci.2008.02.044>
11. Akıncı B, Siviş ZO, Şahin A, Karapınar DY, Balkan C, Kavaklı K, Aydınok Y. Stevens-Johnson Syndrome associated with methotrexate treatment for acute lymphoblastic leukemia: a case report. *Arch Argent Pediatr.* 2018;116(3):e459-e462.